

## Ecological causality of the central serous chorioretinopathy incidence in the Sumy region

Kuzenko O.V.<sup>1</sup>, a Postgraduate Student; Dyomin Yu.A.<sup>1</sup>, Dr. Med. Sc., Prof.;

Litvinova L.V.<sup>1</sup>, Cand. Med. Sc.; Kuzenko E.V.<sup>2</sup>, Dr. Med. Sc.

<sup>1</sup> Kharkiv Medical Academy of Postgraduate Education; Kharkiv (Ukraine)

<sup>2</sup> Sumy State University; Sumy (Ukraine)

E-mail: logvinenok26@gmail.com

### Key-words:

central serous chorioretinopathy, chrome, ecological factor, correlation analysis

**Background.** Studying anthropoecological factors is required to specify risk factors and predictors of central serous chorioretinopathy (CSCR).

**Purpose.** To analyze a level of atmospheric air pollution by Cr<sup>6+</sup> and to assess its influence on the incidence of central serous chorioretinopathy among adult population of the Sumy region.

**Material and Methods.** Data on registration of patients for CSCR treatment (according to ICD-10: H35.7) from 2005 to 2017 were analyzed. The data were obtained in Statistical Department of Sumy Regional Clinical Hospital. Official information data on air pollution by Cr<sup>6+</sup> emission at PJSC Sumy NPO were studied.

**Results.** For the entire period of observation, the CSCR incidence in the Sumy region shows a clear tendency to increase. The correlation analysis confirmed the fact that CSCR is determined by Cr<sup>6+</sup> emission in the atmospheric air and showed a direct (correlation coefficient  $r = 0.85$ ) significant ( $p = 0.0007$ ) relationship (Fig. 3) between the CSCR incidence rate and the levels of Cr<sup>6+</sup> emission in the atmosphere.

**Conclusion.** Cr<sup>6+</sup> was found to have an indirect and induced effect on the CSCR incidence in the Sumy region.

Central Serous Chorioretinopathy (CSCR) is a disease which affects mostly young adults and is characterized by serous detachment of the neurosensory retina, focal multifocal areas of leakage at the level of the retinal pigment epithelium (RPE) as a result of disorders in the barrier and pumping function; CSCR affects the macular area mainly [1]. Chronic macular edema in patients with CSCR causes a stable vision loss due to a thinned foveolar layer of photoreceptors as well as degeneration and atrophy of the pigment epithelium.

Among risk factors for central serous chorioretinopathy are hypertension, viral infection, type A personality, autoimmune disorders, sleeping disturbance, alcohol consumption, high temperature effect (sauna), and vigorous physical activity [7, 11]. At the present time, most physicians entertain an idea that one of the main causes of CSCR is a high level of both exogenous [3, 4] and endogenous [2] steroid hormones in the body. Cases of CSCR in patients with hypothalamo-pituitary-adrenal axis pathology (Cushing's syndrome, stress, pregnancy) are known [5, 6, 8]. A relationship between CSCR development and a *Helicobacter pylori* infectious agent [10] and positive disease regression after eradication [9] is being discussed actively. Balkarli A. et. al. have reported a relationship between CSCR and fibromyalgia syndrome (FMS) [12]. The incidence of FMS was 42.2% in patients

with CSCR compared to 10.4% of controls. Latest papers have associated a risk of CSCR development in women with polycystic ovary syndrome against elevated androgens, testosterone in particular [13].

The presence of a great number of diverse and in some cases contradictory theories of CSCR development [20] speaks for the fact that etiology of the disease is understudied. It might be the lack of the whole picture of etiopathogenic mechanisms of CSCR that causes insufficient efficacy of medical measures, relapses of the disease and chronicity of the process. That is why we want to pay attention to the ecological crisis in the country, connected with the technogenic pollution of the atmosphere, soil and underground water by heavy metals during the modern urbanization and industrialization and their possible influence on CSCR development. It should be pointed that heavy metals, in principle, have no mechanisms of self-purification, i.e., they are not transformable unlike organic compounds, and have cumulative properties.

Considerable attention is paid to the pollution of the environment with compounds of hexavalent chromium (Cr<sup>6+</sup>), which is classified as hazard class I (extremely

dangerous). This form is rare in the nature and is produced mainly in industry. It should be noted that compared with other heavy metals (Cd, Pb, Hg) we have not found in the domestic literature data on studying  $\text{Cr}^{6+}$  compound on eye structures apart from acute pathology of the anterior part of the eyeball which is described in textbooks. Of interest are scientific papers abroad which highlight and analyze in details causes of neurodegenerative changes in the retina and choroid of the eye based on toxic effects of salts of heavy metals [18, 19].

We believe that studying anthropoecological factors, in a result of which the question of the eye disease prevalence becomes of a special significance, is necessary to specify the risk factors and predictors of this pathology.

**Purpose.** To analyze a level of atmospheric air pollution with  $\text{Cr}^{6+}$  and to assess its influence on the incidence of central serous chorioretinopathy in the adult population of the Sumy region.

#### Material and Methods

Data on registration of patients for CSCR treatment (according to ICD-10: H35.7) from 2005 to 2017 were analyzed. The data were obtained in Statistical Department of Sumy Regional Clinical Hospital. Sumy's ecological certificate was studied concerning the levels of environmental pollution with  $\text{Cr}^{6+}$  compounds.

STATISTICA 8 (Serial number 31415926535898) was used to perform mathematical calculations. To generalize the data obtained, the arithmetic mean ( $M$ ) and its standard error ( $\pm m$ ) were used, and the Pearson correlation coefficient ( $r$ ) was used to establish the relationship between the CSCR incidence and the  $\text{Cr}^{6+}$  level in the atmosphere of the Sumy region.

#### Results

Environmental degradation concerns directly the Sumy region, on the territory of which there are chemical industry enterprises located within the city (PJSC Sumy NPO, PJSC Sumykhimprom, PJSC Nasosenergomash, Drill Collars and Kellys Plant Subsidiary Enterprise, Huala Klozhers Ukraine Ltd, Technologia JSC). The activity of the enterprises affects the health condition of the population. Romny, Velyka Pysarivka, Krolevetskyi, Bilopillia, Okhtyrskyi, and Burytskyi Raions can be referred as industrial districts of the region, where the risk of all diseases is more than 70% [17].

Findings of a recent ecological - geochemical research have demonstrated that a level of heavy metals including Cu, Zn, Mn, Ni, Cr, and V was significantly higher in relation to baseline values in the soil, vegetation and natural surface waters of the Psel River, which is a zone of influence of Sumyteploenergo LLC [14].

It is reliably known that main sources of  $\text{Cr}^{6+}$  pollution is electroplating industry, waste of leather factories, circulating cooling systems, production of glue and

washing facilities. A potential hazard for environment is accumulated galvanic sludge in the Sumy region at PJSC Sumy NPO, PJSC Naftoprommash (a city of Okhtyrka). Volumes of electroplating sludge considerably exceed utilization rates and make up about 80 tons per year at nominal load. By 1st January 2016, PJSC Sumy NPO had accumulated 1378.0 tons of the specified wastes [16].

According to Sumy's ecological certificate, the largest source of  $\text{Cr}^{6+}$  emission in the air is PJSC Sumy NPO (Table 1) which is included in the "List of 100 Most polluters in Ukraine".

Figure 1 demonstrates that the CSCR incidence in the Sumy region from 2005 to 2017 was of a wave-like character with a value ranging from 1.2% (5 cases) in 2005 to maximal 16.4% in 2010. However, in general for the entire period of observation, the CSCR incidence in the Sumy region shows a clear tendency to increase.

Based on a correlation analysis between years and CSCR incidence rates in the Sumy region, we revealed a positive significant ( $p = 0.002$ ) relationship (correlation coefficient,  $r = 0.69$ ) (Fig. 2), which indicates a steady increase in the CSRC incidence which we associate with the environmental degradation in the Sumy region.

The correlation analysis confirmed the fact that CSCR is determined by  $\text{Cr}^{6+}$  emission in the air and showed a direct (correlation coefficient  $r = 0.85$ ) significant ( $p = 0.0007$ ) relationship (Fig. 3) between the CSCR incidence rate and the levels of  $\text{Cr}^{6+}$  emission in the atmosphere, indicating an unfavorable further forecast of an increase in the frequency of this pathology in the population.

Taking into account the current state of biosphere pollution by chromium drainage from electroplating industry, Sumy scientists have developed a comprehensive scheme for the purification of chrome-containing wastewater at PJSC "Sumy NPO" using electrocoagulation devices with an efficiency of 99.96% on the basis of PJSC Gluhovsky plant "Electropanel" [15].

Such understanding the problem has forced the Sumy Regional Council to approve the Integrated Waste Management Program in the Sumy Region for 2016-2020, which is aimed at improving the waste management system, reducing the man-made load on the environment and improving the ecological situation in the Sumy region [16].

#### Conclusions

1. Data obtained testify to the complicated epidemiological situation and the ecological causality of central serous chorioretinopathy development.

2.  $\text{Cr}^{6+}$  was found to have an indirect and induced effect on the CSCR incidence in the Sumy region

*Prospects for further research.* Patients with CSCR should be examined in regard of  $\text{Cr}^{6+}$  levels in biological fluids using atomic absorption spectrophotometry.

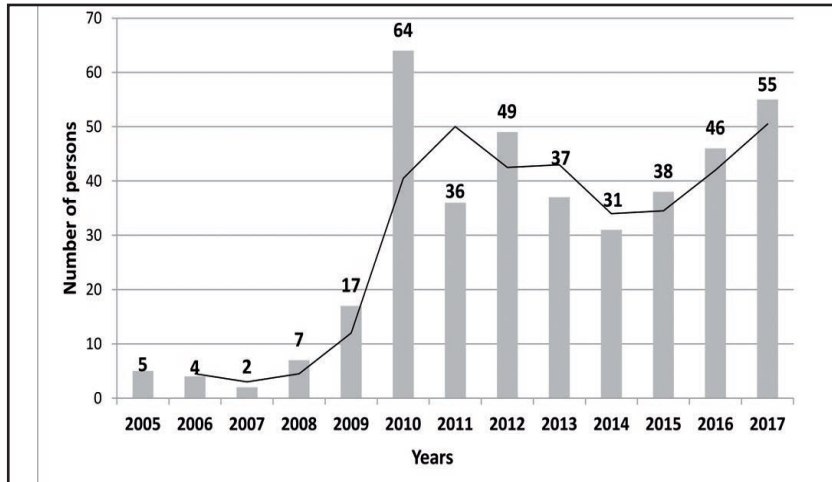
## References

- Moschos M, Brouzas D, Koutsandrea C. Assessment of central serous chorioretinopathy by optical coherence tomography and multifocal electroretinography. *Ophthalmologica*. 2007; 221 (5): 292-298.
- Haimovici R, Rumelt S, Melby J. Endocrine abnormalities in patients with central serous chorioretinopathy. *Ophthalmology*. 2003 Apr;110(4):698-703.
- Kleinberger AJ, Patel C, Lieberman RM, Malkin BD. Bilateral central serous chorioretinopathy caused by intranasal corticosteroids: a case report and review of the literature. *Laryngoscope*. 2011 Sep;121(9):2034-7.
- Stoffelns BM, Kramann C, Schoepfer K. [Central serous chorioretinopathy (CSC) and corticosteroids]. *Klin Monbl Augenheilkd*. 2008 May;225(5):370-5.
- Pastor-Idoate S, Peña D, Herreras JM. Adrenocortical adenoma and central serous chorioretinopathy: a rare association?. *Case Rep Ophthalmol*. 2011 Sep;2(3):327-32.
- Giovansili I, Belange G, Affortit A. Cushing disease revealed by bilateral atypical central serous chorioretinopathy: case report. *Endocr Pract*. 2013 Sep-Oct;19(5):129-33.
- Chatziralli I, Kabanarou SA, Parikakis E, Chatzirallis A, Xirou T, Mitropoulos P. Risk Factors for Central Serous Chorioretinopathy: Multivariate Approach in a Case-Control Study. *Curr Eye Res*. 2017 Jul;42(7):1069-1073.
- Maggio E, Polito A, Freno MC, Pertile G. Multimodal imaging findings in a case of severe Central Serous Chorioretinopathy in an uncomplicated pregnancy. *BMC Ophthalmol*. 2015 Dec 22;15:183.
- Zavoloka O, Bezditko P, Lahorzhevskaya I, Zubkova D, Ilyina Y. Clinical efficiency of *Helicobacter pylori* eradication in the treatment of patients with acute central serous chorioretinopathy. *Graefes Arch Clin Exp Ophthalmol*. 2016 Sep;254(9):1737-42.
- Mateo-Montoya A, Mauget-Fayse M. *Helicobacter pylori* as a risk factor for central serous chorioretinopathy: Literature review. *World J Gastrointest Pathophysiol*. 2014 Aug 15;5(3):355-358.
- Liu B, Deng T, Zhang J. Risk factors for central serous chorioretinopathy: A Systematic Review and Meta-Analysis. *Retina*. 2016 Jan;36(1):9-19.
- Balkarli A, Erol MK, Yucel O, Akar Y. Frequency of fibromyalgia syndrome in patients with central serous chorioretinopathy. *Arq Bras Oftalmol*. 2017 Jan-Feb;80(1):4-8.
- Witmer MT, Klufas MA, Kiss S. Polycystic Ovary Syndrome and Central Serous Chorioretinopathy. *Ophthalmic Surg Lasers Imaging Retina*. 2015 Jun;46(6):684-686.
- Voitiuk Yu Yu, Kuraieva IV, Kroik HA, Matsibora OV, Matviienko OV. [Patterns of the distribution of heavy metals in the objects of the city of Sumy]. *Visnyk Dnipropetrovskoho universytetu. Seriya: heolohiia, heohrafiia*. 2016; 24(2):18–24. In Ukrainian.
- Melnyk OS. [Utilization of wastewaters of galvanic production and their neutralization]: avtoref. dys. na zdobuttia nauk. stupenia kand. tekhn. nauk. 2011: 20. In Ukrainian.
- [Integrated Waste Management Program in Sumy Oblast for 2016-2020]. [Internet]. Available from: <http://www.gkh.sm.gov.ua/index.php/uk/833-kompleksna-programa-povodzhennya-z-vidkhodami-v-sumskij-oblasti-na-2016-2020-roki>. In Ukrainian.
- Skorokhod AV. [Medico-social substantiation of the model of voluntary medical insurance in the system of budget insurance medicine (for example, Sumy region): avtoref. dys. kand. med. nauk]: 14.02.03. Kyiv. 2015; 28. In Ukrainian.
- Jay ER, John MD. Heavy Metal Concentration in Human Eyes. *American Journal of Ophthalmology*. 2005; 139(5): 888-894.
- Ng SK, Ebneter A, Gilhotra JS. Hip-implant related chorioretinal cobalt toxicity. *Indian J. Ophthalmol*. 2013; 61(1): 35 – 37.
- Benedyktova OA, Riukov SA, Suk SA, Saksonov SH. [Central serous chorioretinopathy. New look at etiology and pathogenesis (review of literature)]. *Ukrainskyi naukovomedychnyi molodizhnyi zhurnal*. 2013; 1: 49-52. In Russian.

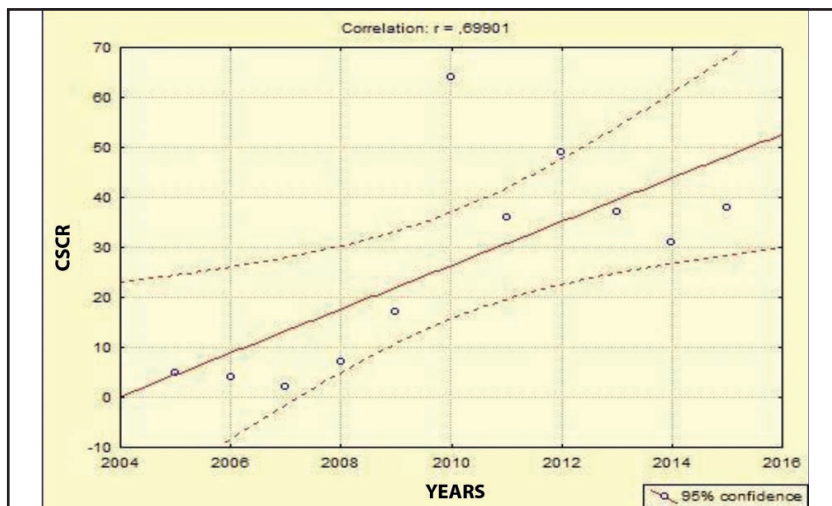
**Table 1.** Emission of Cr<sup>6+</sup> in the atmospheric air according to Sumy's ecological certificate

Years	Percentage of pollutant emissions (Cr <sup>6+</sup> )	
	Total emission, t/year	% to total emissions of the object
2005	0.191	0.01
2006	0.191	0.01
2007	0.192	0.02
2008	0.192	0.02
2009	0.284	0.05
2010	0.284	0.06
2011	0.284	0.06
2012	0.283	0.06
2013	0.22	0.05
2014	0.132	0.064
2015	0.118	0.06
2016	*	*
2017	*	*
(M±m)	0.21±0.018	0.04±0.006

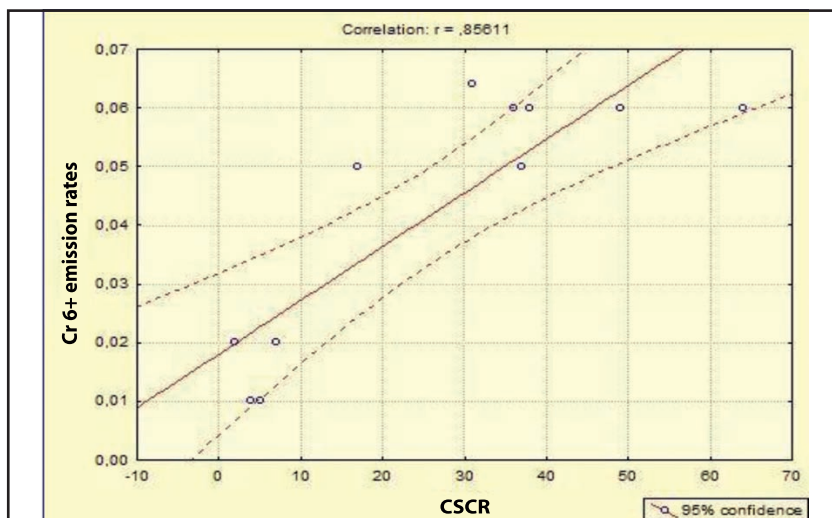
\* Official information Cr<sup>6+</sup> emission into the air has not been available since 2016



**Fig. 1.** Changes in the incidence of central serous chorioretinopathy in the Sumy Region within 2005-2017



**Fig. 2.** A correlation relationship between years and the incidence of central serous chorioretinopathy



**Fig. 3.** A correlation relationship between the incidence of central serous chorioretinopathy and emission of Cr<sup>6+</sup> in the atmospheric air